

blood

2008 112: 449-451
doi:10.1182/blood-2008-04-151613

Hemoglobin normalization after splenectomy in a paroxysmal nocturnal hemoglobinuria patient treated by eculizumab

Antonio M. Risitano, Ludovica Marando, Elisa Seneca and Bruno Rotoli

Updated information and services can be found at:
<http://bloodjournal.hematologylibrary.org/content/112/2/449.full.html>

Information about reproducing this article in parts or in its entirety may be found online at:
http://bloodjournal.hematologylibrary.org/site/misc/rights.xhtml#repub_requests

Information about ordering reprints may be found online at:
<http://bloodjournal.hematologylibrary.org/site/misc/rights.xhtml#reprints>

Information about subscriptions and ASH membership may be found online at:
<http://bloodjournal.hematologylibrary.org/site/subscriptions/index.xhtml>



URD allograft can be performed. However, the high-risk patient population in our study had a low chance of cure with chemotherapy and is typical of patients for whom URD HCT is considered.

Certain patient subsets (high white blood cell count, adverse cytogenetics) clearly do poorly with standard chemotherapy; more than 90% of our reported cohort had 1 or more high-risk features. It is unlikely that a randomized study will ever directly study these high-risk Ph⁻ patients and we must rely on lesser levels of evidence. In the next United Kingdom/United States trial, patients with high-risk features will proceed to URD HCT if a donor is identified and available within a defined interval, permitting donor (related or URD) versus no-donor analyses of outcome. However, these statistical techniques may underestimate the value of the allografts because not all patients with a donor proceed to HCT.

Dr Mehta proposes subtracting 20% from the observed survival of URD HCT series based on a reported average 80% 6-month overall survival for adult ALL patients. However, this proposed 20% subtraction approach does not fully consider and adjust for the differing survival probability from CR1 to HCT based on each individual patient's characteristics, including the time until donor availability and the initiation of either HCT or intensified nontransplantation therapies. This oversimplified approach is likely misleading as it does not distinguish reasons for treatment failure: both early relapse and serious postinduction complications prevent delivery of both intensive chemotherapy and HCT. Importantly, our study analyzed patients from the time of transplantation, not from CR1. To estimate the survival probability since CR1 would require a complete file on the available patients considered for HCT as they achieve CR1; information not available in data reported to the CIBMTR.

Despite the recently published but somewhat dated (and selected) 20+-year series of autografts he cites,² the recently

published nearly 2000-patient UKALL XII/ECOG prospective randomized trial clearly showed that chemotherapy is superior to autografting for adult ALL patients in CR1.³ In addition, the recent CIBMTR long-term follow-up report⁴ noting similarity in outcome in adult ALL between selected (and somewhat lower risk) autografts and earlier era (1989-1998) URD allografts also does not favor a broader application of autotransplantation. Outside of a clinical trial, autografts currently have no clearly defined utility in the management of adult ALL patients.

David I. Marks, Daniel J. Weisdorf, and Mei-Jie Zhang

Conflict-of-interest disclosure: The authors declare no competing financial interests.

Correspondence: Daniel J. Weisdorf, University of Minnesota, 420 Delaware SE, MMC 480, Minneapolis, MN 55455; e-mail: weisd001@umn.edu.

References

1. Marks DI, Perez WS, He W, et al. Unrelated donor stem cell transplantation in adults with Philadelphia negative acute lymphoblastic leukaemia in first complete remission. *Blood*. 2008;112:426.
2. Sirohi B, Powles R, Treleaven J, et al. The role of maintenance chemotherapy after autologous stem cell transplantation for acute lymphoblastic leukaemia in first remission: single centre experience of 100 patients. *Bone Marrow Transplant*. Prepublished on April 14, 2008, as DOI 10.1038/bmt.2008.95.
3. Goldstone AH, Richards SM, Lazarus HM, et al. In adults with standard-risk acute lymphoblastic leukemia, the greatest benefit is achieved from a matched sibling allogeneic transplantation in first complete remission, and an autologous transplantation is less effective than conventional consolidation/maintenance chemotherapy in all patients: final results of the International ALL Trial (MRC UKALL XII/ECOG E2993). *Blood*. 2008;111:1827-1833.
4. Bishop MR, Logan BR, Gandham S, et al. Long term outcomes of adults with acute lymphoblastic leukaemia after autologous or unrelated donor bone marrow transplantation: a comparative analysis by the National Marrow Donor Program and Center for International Blood and Marrow Transplant Research. *Bone Marrow Transplant*. 2008;41:635-642.

To the editor:

Hemoglobin normalization after splenectomy in a paroxysmal nocturnal hemoglobinuria patient treated by eculizumab

In paroxysmal nocturnal hemoglobinuria (PNH), hemolysis is due to the absence on red blood cell (RBC) surface of the 2 complement regulators CD55 and CD59,^{1,2} which causes uncontrolled complement activation and consequent chronic intravascular hemolysis via the membrane attack complex (MAC). Eculizumab,³ a monoclonal antibody against complement fraction 5, has provided clinical benefit in several trials in PNH patients.⁴⁻⁷

A young woman was referred to our department in 2004 for PNH, having received transfusion every 5 to 7 weeks since diagnosis in 1992. Preexisting hemoglobinopathies were excluded by standard laboratory tests. The patient presented severe anemia, normal white blood cell (WBC) and platelet counts, very high serum lactate dehydrogenase (LDH), and unconjugated bilirubin. She entered the double-blind placebo-controlled 26-week phase 3 efficacy and safety study (TRIUMPH) blinded trial⁵ in February 2005, showing no change in laboratory or clinical parameters throughout the 6-month study period (Figure 1); when randomization was disclosed, she was seen to have been assigned to the placebo arm. She entered the subsequent open-label Extension study in September 2005, receiving 600 mg eculizumab weekly for 4 weeks (loading dose) followed by

900 mg fortnightly (maintenance). Approval was obtained from the Federico II University Institutional Review Board for these studies. Informed consent was obtained in accordance with the Declaration of Helsinki. Intravascular hemolysis was soon blocked, as shown by LDH normalization and hemosiderinuria disappearance; as expected, PNH type III RBCs increased from 40% to 70% (Figure 1). But despite preserved marrow function (testified by reticulocytosis and normal WBC and platelets) the patient still required transfusions every 3 to 4 months, even after introduction of recombinant erythropoietin. She showed persistent hyperbilirubinemia, partially due to a Gilbert syndrome (genetically confirmed). While on eculizumab, in vivo study of RBC survival by ⁵¹Cr labeling showed markedly reduced RBC half-life (10 days, normal range 25-35 days) with high spleen and liver counts. In addition, the Coomb test was positive for C3d only, and dual color flow cytometry of the PNH RBCs revealed significant C3b coating (19%).⁸ We hypothesized that eculizumab had blocked intravascular hemolysis, but could not oppose C3b accumulation on RBCs (uncontrolled by the absence of CD55), leading to hemolysis in the reticulo-endothelial system. To control extravascular hemolysis, we

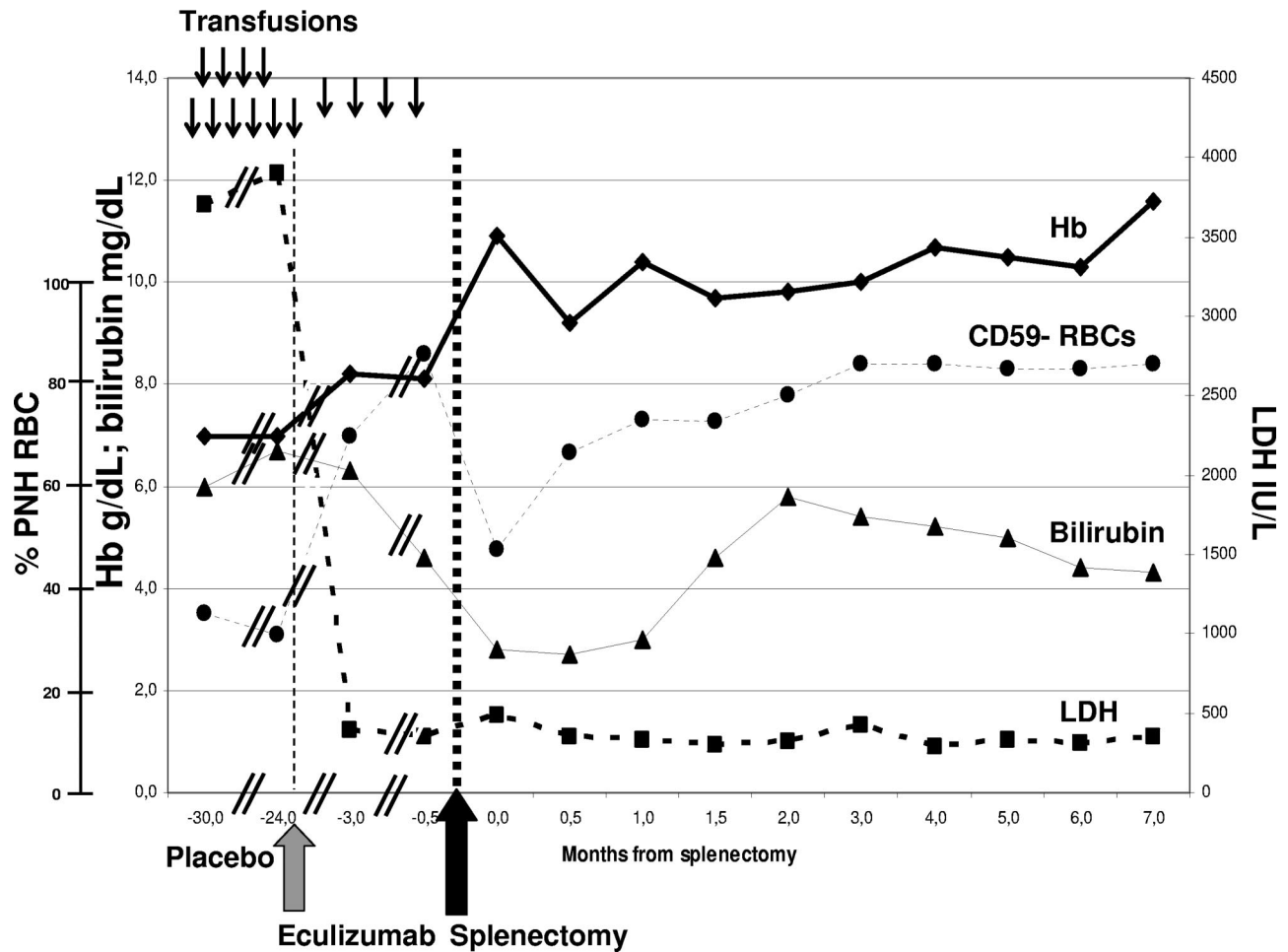


Figure 1. Laboratory parameters in relation to anticomplement treatment and splenectomy. ↓: Two units of packed red cells transfused. Eculizumab (Soliris, Alexion Pharmaceuticals) was started in September 2005 (gray arrow), according to the standard schedule (600 mg weekly $\times 4$, then 900 mg fortnightly). Splenectomy was performed in May 2006 (black arrow), supported by vaccinations and antibiotics. No infections or other clinical complications have been recorded to date. The need for transfusion (17 units in the previous 12 months) remained stable during the TRIUMPH study (placebo arm), and was significantly reduced after introduction of eculizumab, which resolved intravascular hemolysis with LDH normalization; however, transfusion independence with hemoglobin stabilization was achieved only after splenectomy. Bilirubinemia was persistently elevated (almost entirely unconjugated) with some fluctuations, in part due to associated Gilbert syndrome (genetically confirmed by the presence of homozygous (TA)₇ polymorphism of the *UGT1A1* gene).

decided to remove the spleen, which was slightly enlarged (500 mL, by ultrasound scan). The patient underwent video-laparoscopic splenectomy, without complications; she received standard anti-infectious prophylaxis measures, including anti-haemophilus and anti-pneumococcal vaccination. Eight months after surgery hemoglobin was stable at more than 110 g/L (11 g/dL) without transfusion, bilirubin was only slightly elevated, and flow cytometry revealed a further increase of PNH RBC to 85% (Figure 1), and 41% of C3⁺ PNH RBCs.

Splenectomy has been anecdotally reported in PNH patients not receiving anticomplement therapy, with limited benefit.¹ This is the first case of splenectomy in a PNH patient on eculizumab to resolve extravascular hemolysis. Our report suggests that extravascular hemolysis (mainly in the spleen), that is unapparent in untreated PNH patients due to the rapid clearance of circulating PNH RBCs, may play a pathogenic role in PNH when MAC-mediated lysis is blocked by the complement inhibitor eculizumab. The role of specific C3 split products in this process has not yet been pinpointed in PNH patients, but in other settings (red cell aging, cold agglutinin disease)^{9,10} C3b has been reported to lead to extravascular hemolysis, while the conversion to iC3b and C3d may be protective. Different rates of extravascular hemolysis in

different PNH patients may stem from the pattern of C3 split products and/or polymorphisms of complement receptor and complement regulator molecules. A better understanding of the disease mechanism in PNH in the eculizumab era may pave the way to additional strategies to optimize the clinical efficacy of complement inhibitors in this disease.

Antonio M. Risitano, Ludovica Marando, Elisa Seneca, and Bruno Rotoli

We thank the colleagues of the "Casa Sollievo della Sofferenza" Hospital (S. Giovanni Rotondo, FG) who referred the patient to us (Pellegrino Musto, Severio Mantuano, Angelo Michele Carella), and who performed the ⁵¹Cr study (Filippo Barbano) and splenectomy (Angelo Ambrosio); Alexion Pharmaceuticals (Cheshire, CT) was the promoter of the eculizumab clinical trials.

Conflict-of-interest disclosure: A.M.R. and B.R. have received lecture fees and a research grant and have served as consultants on the Advisory Committee for Alexion Pharmaceuticals. The remaining authors declare no competing financial interests.

Correspondence: Antonio Maria Risitano, Hematology Section, Department of Biochemistry and Medical Biotechnologies, Federico II University, Via Pansini 5, Naples, Italy 80131; e-mail: amrsita@unina.it.

References

1. Parker C, Omine M, Richards S, et al. International PNH Interest Group. Diagnosis and management of paroxysmal nocturnal hemoglobinuria. *Blood*. 2005;106:3699-3709.
2. Wilcox LA, Ezzell JL, Bernshaw NJ, Parker CJ. Molecular basis of the enhanced susceptibility of the erythrocytes of paroxysmal nocturnal hemoglobinuria to hemolysis in acidified serum. *Blood*. 1991;78:820-829.
3. Rother RP, Rollins SA, Mojcik CF, Brodsky RA, Bell L. Discovery and development of the complement inhibitor eculizumab for the treatment of paroxysmal nocturnal hemoglobinuria. *Nat Biotechnol*. 2007;25:1256-1264.
4. Hillmen P, Hall C, Marsh JC, et al. Effect of eculizumab on hemolysis and transfusion requirements in patients with paroxysmal nocturnal hemoglobinuria. *N Engl J Med*. 2004;350:552-559.
5. Hillmen P, Young NS, Schubert J, et al. The complement inhibitor eculizumab in paroxysmal nocturnal hemoglobinuria. *N Engl J Med*. 2006;355:1233-1243.
6. Hillmen P, Muus P, Duhrsen U, et al. Effect of the complement inhibitor eculizumab on thromboembolism in patients with paroxysmal nocturnal hemoglobinuria. *Blood*. 2007;110:4123-4128.
7. Brodsky RA, Young NS, Antonioli E, et al. Multicenter phase 3 study of the complement inhibitor eculizumab for the treatment of patients with paroxysmal nocturnal hemoglobinuria. *Blood*. 2008;111:1840-1847.
8. Risitano AM, Hill A, Ricci P, et al. Paroxysmal nocturnal hemoglobinuria (PNH) in the eculizumab era: the bedside and beyond. *Haematologica*. 2007;92(S3):89. Abstract PO-087.
9. Shapiro S, Kohn D, Miller B, Gershon H. Erythrocytes from young but not elderly donors can bind and degrade immune complex- and antibody-bound C3 in vitro. *Clin Exp Immunol*. 1994;95:181-190.
10. Jaffe CJ, Atkinson JP, Frank MM. The role of complement in the clearance of cold-agglutinin-sensitized erythrocytes in man. *J Clin Invest*. 1976;58:942-949.